

Enhancement on Enlarge Image for Identification Lumbar Radiculopathy at Magnetic Resonance Imaging (MRI)

By Jufriadif Na`am

Enhancement on Enlarge Image for Identification Lumbar Radiculopathy at Magnetic Resonance Imaging (MRI)

Yuhandri ¹, Johan Harlan ², Julius Santony ¹, Rahmat Hidayat ³, Jufriadif Na`am ¹

Abstract – Spinal nerve root pinched by herniated intervertebral disc will yield to painful complaints. Such condition in medical term is called as radiculopathy. The lesion usually occurs in the lower part of vertebral column, i.e. lumbar radiculopathy. To ascertain the diagnosis, the patient should undergo magnetic resonance imaging (MRI) examination. Further image processing is needed to aid the interpretation of these MRI images. The data in this study consisted of 40 MRI images, obtained by using General Electric Brivo MR 355 in T2-weighted sagittal relaxation phase, to be processed later by enlarged and enhancement processing. The image processing produced larger and clearer images, making it easier to observe lumbar radiculopathy. This method serves as a new breakthrough for the health providers in the management of lumbar radiculopathy patients.

Keywords – Enlarge, Enhancement, Lumbar Radiculopathy, Magnetic Resonance Imaging (MRI), Vertebral Column.

13

1. Introduction

Radiculopathy refers to pain, numbness, or paresthesia due to nerve root compression in vertebral column. It is generally described as pinching of spinal nerve root by herniated intervertebral disc. The nerve root controlled a lot somatic muscles, hence the compression will produce painful sensation in the muscles. Even a light external touch can exacerbate painful sensation [1]. Low back pain still constitutes a major medical problem, as the neural [2].

The common symptoms in radiculopathy are painful sensation in the neck, back, arms, or legs. Pain sensation may be increased by coughing, sneezing, or even just a slight change of body position [3]. The disease may weaken limb and pelvic muscles, influencing the walking gait of the patient [4].

To obtain better understanding of radiculopathy disorder, the patient should undergo medical imaging examination [5, 6, 7]. The most appropriate imaging examination in this condition is magnetic resonance imaging, albeit its relatively high cost [8]. MR images show clearly nerve roots in vertebral column,

so we can observe any pinching nerve root [9]. MR images may also expose other radiological disorders i.e. degenerative changes, arthritis, as well as other signs of radiculopathy. The regions of vertebral column in a MR image are showed below (Figure 1).

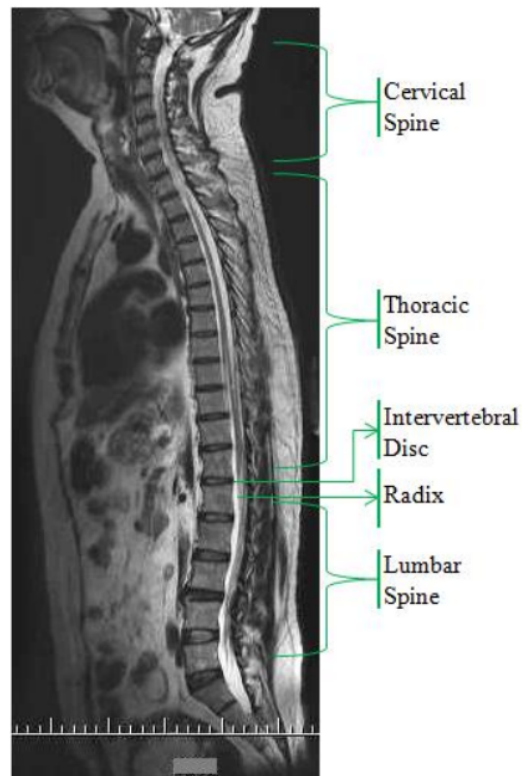


Figure 1. Regions of vertebral column in a MR image

Based upon the segmental regions of vertebral column, spinal nerve radiculopathies are divided into cervical (upper region), thoracic (middle region), and lumbar (lower region) ones. Among the three types of radiculopathies, most of the patients suffered from disorder in the lumbar part [10]. This is due to the greater impact of body weight in the lower region of vertebral column. This type of disorder is called lumbar radiculopathy. The disorder can get worsen if it is not treated immediately. In the chronic phase, it may result in numbness in the legs [11]. Patients with

11

lumbar radiculopathy in the disorder of an absolute indication should surgery [12].

Some MR imaging studies to diagnose lumbar radiculopathy such as Nguyen et al (2016) used upright imaging to accentuate disc pathology to obtain better diagnosis [13]. Harrell (2017) wrote that MR imaging was appropriate whether in acute, subacute, or chronic lumbar radiculopathy [14]. Marrison and Karantanas (2017) claimed that MR image can show soft tissue infection in the lumbar region [15].

Punarselvam and Suresh (2018) performed MR image processing to investigate human lumbar spine using finite element method (FEM) and soft computing techniques. Their method implemented filter techniques (Gaussian filter, bilateral filter, and median filter) and edge detection algorithm (Canny, Sobel, Prewitt, and Roberts). Canny algorithm resulted better images than other algorithms [16]. Al Kafri et al (2017) conducted a study to determine location of lumbar spinal disc in MR images based upon Pixels Coordinate and Gray Level Features. The best weighting were obtained in using Weighted K-Nearest Neighbor (KNN) and Fine Gaussian Support Vector Machine (SVM) techniques [17].

The most difficult element in elaborating clinical information from MR imaging is to determine the magnitude of nerve root compression [18], although MR imaging can show the location of pinching nerve root [19]. Hence, the result of MR imaging does not render great contribution in the treatment of nerve root radiculopathy [20]. As MR imaging does not render qualified evidence in diagnosing nerve root compression, medical doctors rely more on patient medical record in determination of clinical decision [21]. The MR image processing in this study aims to obtain better elements in radiculopathy images to facilitate easier diagnosis.

2. Material and method

Dataset to be analyzed are secondary ones, namely MR Image. MR images constitute one type of medical images. To facilitate the analysis later, the images should undergo medical image processing. Medical image processing aims to facilitate the user in conceiving the disease, which in turn aids in its medical care and treatment. MR imaging in patients suspected of lumbar radiculopathy is indispensable for radiologists. Medical image processing facilitate the users to observe objects suspected of causing lumbar radiculopathy, hence the putative causes of lumbar radiculopathy can be well evaluated. The medical image processed in this study was recorded using General Electric brand Brivo MR355 type MRI equipment. The recording technique used a T2-

weighted sagittal relaxation phase, producing 40 images of 40 Lumbar Radiculopathy patients. Each patient has a complaint of back and/or leg pain.

Each image is stored using the Joint Photographic Experts Group (jpg) format with truecolor color structure. Furthermore, the image is processed using Matlab R2017a software using image processing methods. The main image processing method to be used is Enlarge and Enhancement with the process steps showed in Figure 2.

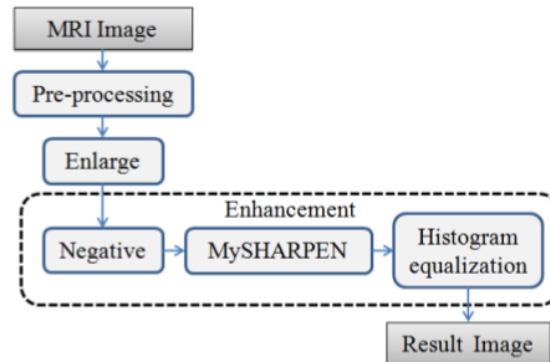


Figure 2. Stages of processing

2.1. Pre-processing

Image pre-processing is the stage of image preparation that should be dealt first before being analyzed. The goal of this image pre-processing should be precisely determined beforehand so that there should be no errors in the next process. Pre-processing in this study is the cropping process.

Cropping is performed to get Area of Interest that is free from unnecessary areas. The cropping technique to be performed is manual method [22], i.e. to set the initial corner point and the required area. The whole required area must be within the input image. The cropping area here will still contain unnecessary regions. Cropping algorithm is showed in Figure 3.

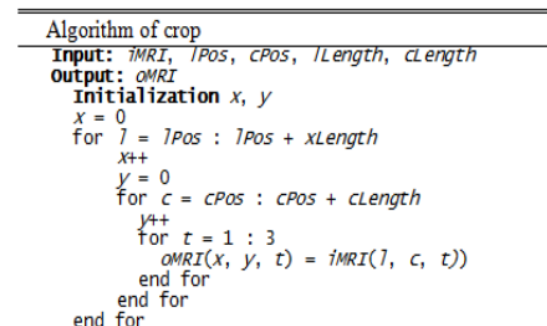


Figure 3. Cropping Algorithm

Where:

- $iMRI$: input MR image
- $oMRI$: output cropping image
- $lPos$: initial pixel row of cropping area
- $cPos$: initial pixel column of cropping area
- $iLength$: length of pixel row in cropping area
- $cLength$: length of pixel column in cropping area
- x : pixel row of output cropping image
- y : pixel column of output cropping image
- l : pixel row of input image
- c : pixel column of input image
- t : color value

2.2. Enlarge

The next process is to enlarge the physical size of the image. The larger the size of the image, the larger the objects contained within the image. With the new magnitude of this object, it will be easier to observe the putative objects that may cause the disease.

The technique to be used is Line-Column Interpolation (LCI) [23]. In the technique we add pixels between adjacent pixels rows and columns. The value of the new pixel is obtained from the average of two adjacent pixel values. The equation used in enlarging process is shown in the following equation:

$$zMRI = 2 \cdot oMRI - 1 \quad (1)$$

$$zMRI_{(l,c,t)} = oMRI_{(l+1,c,t)} \quad (2)$$

$$zMRI_{(l,c,t)} = \frac{zMRI_{(l-1,c,t)} + zMRI_{(l+1,c,t)}}{2} \quad (3)$$

$$zMRI_{(l,c,t)} = \frac{zMRI_{(l,c-1,t)} + zMRI_{(l,c+1,t)}}{2} \quad (4)$$

The equation (1) to (4) serves to enlarge the image. Equation (1) is a function to add pixels as much as twice the number of pixels in the original image minus 1. In this process we add the rows by 2 times minus 1 [14] add the columns by 2 times minus 1. Mapping of the pixel values of the input image into the pixel values of the enlarged image is showed in equation (2). To fill the empty values of the new pixels, we use the equation (3) for the row position and equation (4) for the column position.

2.3. Enhancement

Enhancement is an important feature in most image processing methods that are incorporated within a lot of image processing applications [24]. This process aims to improve image quality by clarifying objects contained in the image. In this process we add or subtract pixel values of certain objects, so that every object can be distinguished significantly. Three techniques used in this

enhancement process consists of negative, mysharpen and histogram equalization.

Negative is the process of reversing the pixel value of its highest value, namely 255. The purpose of this process is to give a pixel value opposite of the pixel value of the original image, so that dark objects will become brighter. The equation used can be seen in equation (5) below.

$$mMRI_{(l,c,t)} = 255 - zMRI_{(l,c,t)} \quad (5)$$

Where:

- $mMRI$: mirror output image

MySHARPEN is the process of maximizing the value of a high pixel group or minimizing the pixel value of a low group. Pixel grouping is based on the image multithreshold values. The purpose of this process is to provide a striking difference (widen the distance) of the group of pixels with the lowest or highest value with the value of the middle group. This process was to support other processes in forming edge detection. Because it is difficult to design an algorithm, which could detect correct edges [25], [26]. This process forms the boundaries of the object clearly (edge enhancement). The equation used can be seen in equation (6).

$$pMRI_{(l,c,t)} = \begin{cases} mMRI_{(l,c,t)}/2, & mMRI_{(l,c,t)} \leq T_1 \\ mMRI_{(l,c,t)}, & T_1 < mMRI_{(l,c,t)} < T_{n-1} \\ mMRI_{(l,c,t)} \cdot 2, & mMRI_{(l,c,t)} \geq T_n \end{cases}$$

Where:

- $pMRI$: MySHARPEN output image
- T : multithreshold

Histogram equalization is the process of improving image quality equalizing the color histogram of each pixel. Each pixel value has similar number of occurrences in an image. The results of this process further clarify objects in the image, because they remove objects that are too dark and objects that are too bright. The equation used can be seen in equation (7) below.

$$eMRI_{(l,c,t)} = \frac{k eMRI_{(l,c,t)} T}{Lc} \quad (7)$$

Where:

- $eMRI$: output image of histogram equalization
- k : cumulative histogram

3. Result and discussion

MRI images of the spine can reveal radix degenerative changes caused by Lumbar

Radiculopathy. This imaging is needed by the doctors in establishing diagnostics. Diagnostic results are needed in making decision, whether the patient should be treated conservatively using physiotherapy, rehabilitation, and pain medication or be advised to undergo surgery.

Irritation to a certain radix may result to its inability to withstand pressure from the intervertebral disc, led to the protrusion of intervertebral disc into radix area. This is called as lumbar radiculopathy that can be observed in MR images. The image is showed in Figure 4.

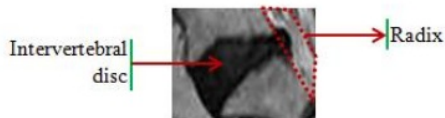
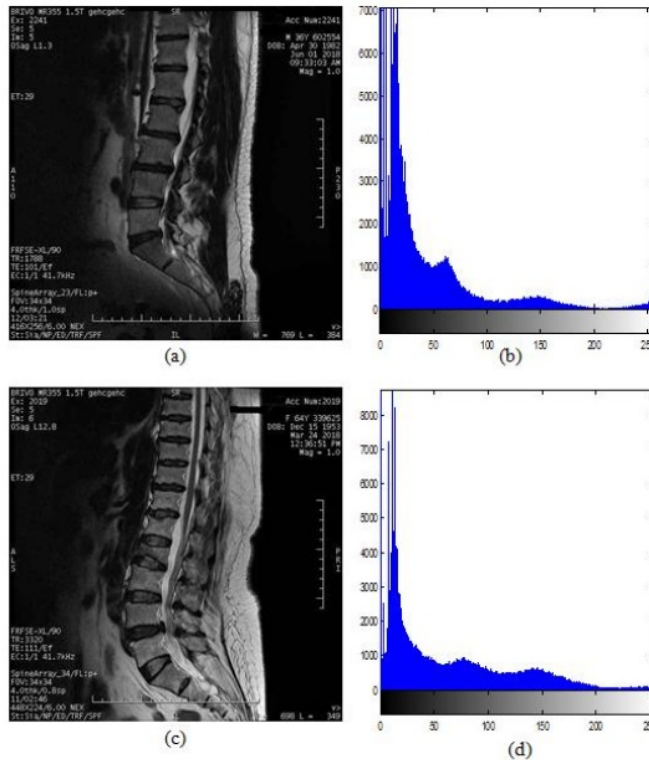


Figure 4. Intervertebral disc protrusion into radix area

The images processed in this study were MR images of patients suspected of having lumbar

radiculopathy based on the reference of a neurologist. We got 40 images, acquired by General Electric Brivo MR355 equipment in T2-weighted sagittal relaxation phase, stored in Joint Photographic Experts Group (JPG) format with true color type. In this article, only 2 images are shown. One image has relatively large pixel values while the other has small ones, with a relatively dark and a relatively bright image of the spinal structure. To find out the level of blackness, the image is converted to the gray level type. Images that have a relatively dark image of the spinal structure have pixel values closer to 0 more than that of the relatively bright one. Figure 5 (a) shows an input image with a dark structure picture with the composition of the pixel values showed in Figure 5 (b). Figure 5 (c) shows an input image with a bright spine structure picture with the pixel values configuration showed in Figure 5 (d).



9 Figure 5. Darker and brighter input image
 (a) Input image-1 (darker), (b) Pixel values composition of input image-1,
 (c) Input image-2 (brighter), (d) Pixel values composition of input image-2

The input images showed in Figure 5 (a) and Figure 5 (c) were processed according to the processing sequence showed in Figure 2. The programming language used in this image processing

was R2017, a version of Matlab. The image generated from each processing is stored in memory, whereas the display can be seen in Figure 6.

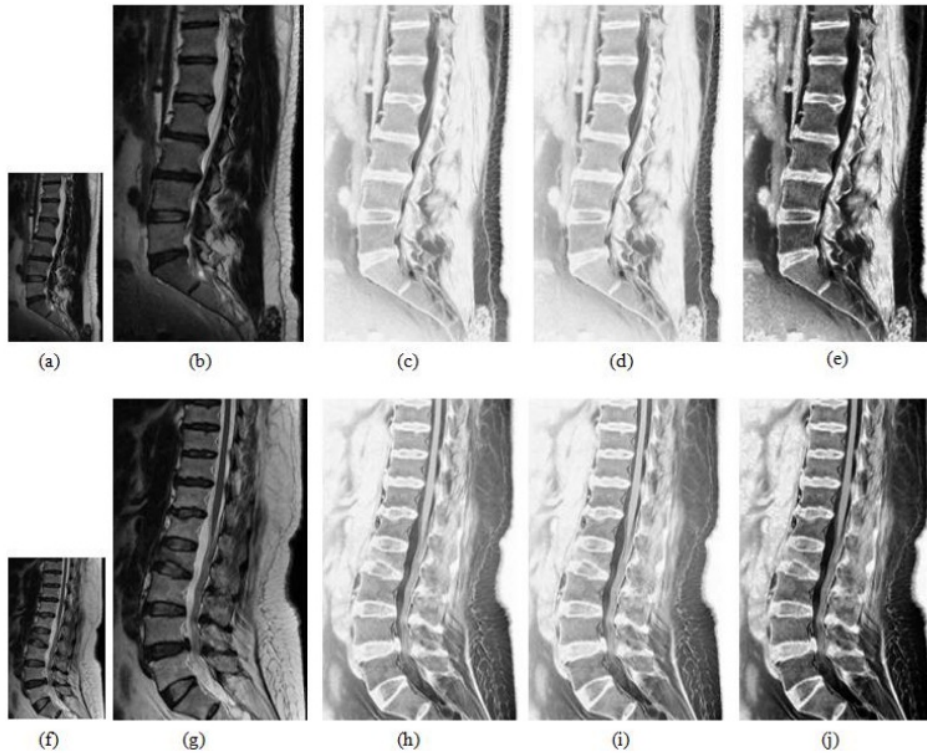


Figure 6. Image processing (a) Input image-1, (b) Enlarged image-1, (c) Negative of image-1, (d) MySharpen of image-1, (e) Histogram equalization of image-1, (f) Input image-2, (g) Enlarged image-2, (h) Negative of image-2, (i) MySharpen of image-2, (j) Histogram equalization of image-1

The input images in Figure 5 (a) and Figure 5 (c) still contain many areas unnecessary for lumbar radiculopathy diagnosis. Hence, these images were cropped to remove unnecessary areas for the diagnosis. The cropping results are showed in Figure 6 (a) and Figure 6 (f).

In the cropped images, there are 5 lumbar segments (L) of the vertebral column, namely L1 - L5, and 6 intervertebral lumbar disc (LD), namely LD1 - LD6. Numbering of L1 to L5 and LD1 to LD6 start from above. Each of the six intervertebral discs is attached directly to the adjacent lumbar segments of vertebral column, which characterizes lumbar radiculopathy. LD1 is attached to L1, LD2 is attached to L1 and L2, LD3 is attached to L2 and L3, LD4 attached to L3 and L4, LD5 is attached to L4 and L5, and LD6 is attached to L5. The structure of Lumbar numbering and cropped Disc of Figure 6 (a) is showed in Figure 7. The numbering will be used further in the explaining of the diagnosis.

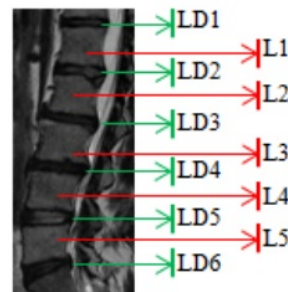


Figure 7. The structure of lumbar and intervertebral disc numbering

The cropped images were then enlarged with enlarging process, so the objects contained in the images are also enlarged. Enlargement of these objects will facilitate the diagnosis, enabling the user to observe the changes in the shape and structure of the disc more clearly. The changes in shape and structure of the disc is caused by lumbar radiculopathy. The enlarged images are showed in Figure 5 (b) and Figure 5 (g).

The enlarged images were processed further to enhance or improve their qualities. The qualityimprovement process changes the pixel

values of each object in the image, so each object can be easily observed. The main object of the lumbar radiculopathy is the intervertebral disc, which is simply called a disc in this article. The disc consists of the soft nucleus pulposus (NP) which is surrounded by a strong annulus fibrosus (AF).

To further facilitate the observation, the pixel values in the image are negated. The goal is to give a greater difference between pixels. Because AF is a hard structure, its pixels on MR imaging has a black color (pixel values close to 0). Likewise with the soft structures such as NP or Radix, their pixels have white color (close to 255). The negative process will reverse these values into the opposite ones, so the difference among the objects will be more pronounced. The results of this change are showed in Figure 6 (c) and Figure 6 (h).

For the structures that are not too hard neither too soft, MySHARPEN process is then carried out. This process will maximize the pixel values that are nearly 255 to be 255 and the pixel value nearly 0 to be 0. So the difference between each object will be more clearly observed. The results of this processes are showed in Figure 6 (d) and Figure 6 (i).

Non-AF and NP objects have pixel values ranging from those of AF to NP. The spread of pixel values of these objects is closer to the middle average values. To further clarify the object, histogram equalization process is carried out, so the colors of these objects are similar to the initial MRI results. In the final results of this enhancement process we can observed significant color differences with respect to AF, NP and other objects. These final images are showed in Figure 6 (e) and Figure 6 (j). Then lumbar radiculopathy can be observed easily based on the characteristics of NP objects that penetrate the AF area on the radix side. The penetrated AF area led to lumbar radiculopathy, as shown in LD6 at Figure 6 (e) and in LD 5 at Figure 6 (j).

4. Conclusions and Future work

Based on our last image in this study, we conclude that enlarge and enhancement process is very helpful in observing lumbar radiculopathy features in the MR images. By facilitating the observations of these features, we hope that it will also be helpful for medical doctors in the future to treat and manage lumbar radiculopathy patients clinically.

Acknowledgements

We would like to thank to Mrs. Ellyzarti as a Senior Radiographer of Department of Radiology at Santa Maria Hospital, Indonesia.

References

- [1]. Ferri, F. F. (2010). *Ferri's Netter Patient Advisor 2010-2011*. Elsevier. Doi: 10.5860/choice47-2930
- [2]. Gunn, C. C., Byrne, D., Chaeo, H., Chapman, L., Lam, A., Leung, M. K., McBrinn, J., Wong, K., & Yan, K. (2007). Upper Lumbar Radiculopathy – A Seldom Detected Cause of Back Pain. *Journal of Orthopaedic Medicine*, 29(3), 79-84. Doi: 10.1300/J094v15n04_12
- [3]. Rana, A. Q., Ghouse, A. T., & Govindarajan, R. (2017). *Radiculopathies. In Neurophysiology in Clinical Practice. In Clinical Practice*. Springer, Cham, 91-98. Doi: 10.1007/978-3-319-39342-1_11
- [4]. Cubo, E., & Goetz, C. G. (2014). *Gait and Gait Disorders. In M. J. Aminoff, and R. B. Daroff (Ed.), Encyclopedia of the Neurological Sciences*, Elsevier Inc. 385-387.
- [5]. Jensen, O. K., Nielsen, C. V., Sørensen, J. S., & Stengaard-Pedersen, K. (2015). Back pain was less explained than leg pain: a cross-sectional study using magnetic resonance imaging in low back pain patients with and without radiculopathy. *BMC Musculoskeletal Disorders*, 16(374), 1-15. Doi: 10.1186/s12891-015-0827-4
- [6]. Bono, C.M., Ghiselli, G., Gilbert, T.J., Kreiner, D.S., Reitman, C., Summers, J.T., Baisden, J.L., Easa, J., Fernand, R., Lamer, T., et al. (2011). An evidence-based clinical guideline for the diagnosis and treatment of cervical radiculopathy from degenerative disorders. *Spine Journal* 11, 64–72. Doi: 10.1016/j.spinee.2010.10.023
- [7]. Tolba, R. (2017). *Radiculopathy. In Pope J., Deer T. (eds) Treatment of Chronic Pain Conditions*, Springer: New York. 253-255. Doi: 10.1007/978-1-4939-6976-0_74
- [8]. Klein, M. A. (2017). Reuse and reduce: abdominal CT, lumbar spine MRI, and a potential 1.2 to 3.4 billion dollars in cost savings. *AbdomRadiol*, 42(12), 2940–2945. Doi: 10.1007/s00261-017-1201-9
- [9]. Albers, S. L. & Latchaw, R. E. (2018). *Radiology of the Spine for the Interventionalist, in Manchikanti L., Kaye A., Falco F., Hirsch J. (eds) Essentials of Interventional Techniques in Managing Chronic Pain*, Springer: Cham, 89-108. Doi: 10.1007/978-3-319-60361-2_8
- [10]. Moon, S.H., Park, J.Y., Cho, S.S., Cho, H.S., Lee, J.Y., Kim, Y.J., & Choi, S.S. (2016). Comparative effectiveness of percutaneous epidural adhesiolysis for different sacrum types in patients with chronic pain due to lumbar disc herniation A propensity score matching analysis. *Medicine (United States)*, 95(37). Doi: 10.1097/MD.0000000000004647
- [11]. Floeth, F., Riemenschneider, M., & Herdmann, J. (2010). IntraleSIONAL hemorrhage and thrombosis without rupture in a pure spinal epidural cavernous angioma: A rare cause of acute lumbal radiculopathy.

- European Spine Journal*, 19(2), 31-37. Doi: 10.1007/s00586-010-1345-6
- [12]. Benditz, A., Madl, M., Loher, M., Grifka, J., Boluki, D., & Linhardt, O. (2016). Prospective medium-term results of multimodal pain management in patients with lumbar radiculopathy. *Scientific Reports*, 6. Doi: 10.1038/srep28187
- [13]. Nguyen, H. S., Doan, N., Shabani, S., Baisden, J., Wolfla, C., Paskoff, G., Shender, B., & Stemper, B. (2016). Upright magnetic resonance imaging of the lumbar spine: Back pain and radiculopathy. *Journal of Craniovertebral Junction & Spine*, 7(1). 31–37. Doi: 10.4103/0974-8237.176619
- [14]. Harrell, G. (2017). *Back Pain*, in B. Desai, and A. Desai (Ed.), *Primary Care for Emergency Physicians*. Springer Nature: Cham, Switzerland. 247-259. Doi: 10.1007/978-3-319-44360-7_23
- [15]. Morrison, W. B., & Karatanas, A. H. (2017). *Infection*, in J. Hodler, R. A. Kubik-Huch, and G. K. von Schulthess (Ed.), *Musculoskeletal Diseases 2017-2020*. Springer Nature: Cham, Switzerland. 71-81. Doi: 10.1007/978-3-319-54018-4_7
- [16]. Punarselvam, E., & Suresh, P. (2018). Investigation on human lumbar spine MRI image using finite element method and soft computing techniques. *Cluster Comput.* 1-17. Doi: 10.1007/s10586-018-2019-0
- [17]. Al Kafri, A.S., Sudirman, S., Hussain, A.J., Fergus, P., Al-Jumeily, D., Al Smadi, H., Khalaf, M., Al-Jumaily, M., Al-Rashdan, W., Bashtawi, M., et al. (2017). *Lumbar spine discs labeling using axial view MRI based on the pixels coordinate and gray level features*. In *Lecture Notes in Computer Science (Including Subseries Lecture Notes in Artificial Intelligence and Lecture Notes in Bioinformatics)*. Springer Verlag. 107–116. Doi: 10.1007/978-3-319-63315-2_10
- [18]. Kuijper, B., Beelen, A., Van Der Kallen, B. F., Nollet, F., Lycklama A Nijeholt, G. J., De Visser, M., & Tans, J. T. J. (2011). Interobserver agreement on MRI evaluation of patients with cervical radiculopathy. *Clinical Radiology*, 66(1), 25–29. Doi: 10.1016/j.crad.2010.07.010
- [19]. Bartoloni, A., Rimondi, E., Guglielmi, G., & Bazzocchi, A. (2017). Low Back Pain Imaging Management in the Elderly Population. *Curr Radiol Rep*, 5(4). Doi: 10.1007/s40134-017-0194-z
- [20]. Cohen, S. P., Gupta, A., Strassels, S. A., Christo, P. J., Erdek, M. A., Griffith, S. R., ... Vu, T. N. (2012). Effect of MRI on treatment results or decision making in patients with lumbosacral radiculopathy referred for epidural steroid injections: A multicenter, randomized controlled trial. *Archives of Internal Medicine*, 172(2), 134–142. Doi: 10.1001/archinternmed.2011.593
- [21]. Tawa, N., Rhoda, A., & Diener, I. (2017, February 23). Accuracy of clinical neurological examination in diagnosing lumbo-sacral radiculopathy: A systematic literature review. *BMC Musculoskeletal Disorders*. BioMed Central Ltd. Doi: 10.1186/s12891-016-1383-2
- [22]. Na`am, J., Harlan, J., Madenda, S., Santony, J., & Suharinto, C. (2018). Detection of proximal caries at the molar teeth using edge enhancement algorithm. *International Journal of Electrical and Computer Engineering (IJECE)*, 8(5), 3259-3266. Doi: 10.11591/ijece.v8i5.pp3259-3266
- [23]. Na`am, J., Santony, J., Yuhandri, Sumijan, & Nurcahyo, G. W. (2018). Enlarge Medical Image using Line-Column Interpolation (LCI) Method, *International Journal of Electrical and Computer Engineering (IJECE)*, 8(5), 3620-3626. Doi: 10.11591/ijece.v8i5.pp3620-3626
- [24]. Jajwara R.R., & Agnihotri R.B. (2020) *Image Enhancement of Historical Image Using Image Enhancement Technique*. In: Saini H., Sayal R., Buyya R., Aliseri G. (eds) *Innovations in Computer Science and Engineering. Lecture Notes in Networks and Systems*, vol 103. Springer, Singapore. Doi: 10.1007/978-981-15-2043-3_28
- [25]. Gunawan, T. S., Yaacob, I. Z., Kartiwi, M., Ismail, N., Za`bah, N. F., & Mansor, H. (2017). Artificial neural network based fast edge detection algorithm for mri medical images. *Indonesian Journal of Electrical Engineering and Computer Science*, 7(1), 123–130. Doi: 10.11591/ijeecs.v7.i1.pp123-130
- [26]. Bawage, S., & Momin, B. (2018). Detection of diseases on crops & design of recommendation engine: A review. In *Smart Innovation, Systems and Technologies* (Vol. 83, pp. 390–398). Springer Science and Business Media Deutschland GmbH. Doi: 10.1007/978-3-319-63673-3_48

Enhancement on Enlarge Image for Identification Lumbar Radiculopathy at Magnetic Resonance Imaging (MRI)

ORIGINALITY REPORT

6%

SIMILARITY INDEX

PRIMARY SOURCES

- 1 iom3.tandfonline.com 18 words — 1%
Internet
- 2 Nicola, Ernesto Miguel (Dr. habil. Markus Bär, Prof. Dr. H. Engel, Prof. Dr. P. Fulde, Prof. Dr. U. Bahr and Technische Universität Dresden, Mathematik und Naturwissenschaften, Physik, Max-Planck-Institut für Physik komplexer Systeme). "Interfaces between Competing Patterns in Reaction-diffusion Systems with Nonlocal Coupling", Saechsische Landesbibliothek- Staats- und Universitaetsbibliothek Dresden, 2002. 18 words — 1%
Publications
- 3 Jufriadif Na'am, Johan Harlan, Irawadi Putra, Romi Hardianto, Mutiana Pratiwi. "An Automatic ROI of The Fundus Photography", International Journal of Electrical and Computer Engineering (IJECE), 2018 18 words — 1%
Crossref
- 4 Vangala Venkata Ramana, Mamidi Sreenivas. "A Continuous Calibration Scheme to Improve Playability on Optical Media Digest of Technical Papers", 2007 Digest of Technical Papers International Conference on Consumer Electronics, 2007 17 words — 1%
Crossref
- 5 E. Punarselvam, P. Suresh. "Investigation on human lumbar spine MRI image using finite element method and soft computing techniques", Cluster Computing, 2018 13 words — < 1%
Crossref

Joseph Prahlow. "Overview of Anatomy and Physiology", Forensic

- 6 Pathology for Police Death Investigators Attorneys and Forensic Scientists, 2010
Crossref 12 words — < 1%
-
- 7 www.springerprofessional.de
Internet 11 words — < 1%
-
- 8 radiologyassistant.nl
Internet 10 words — < 1%
-
- 9 Bhargava, Chitresh, and Nidhi Verma. "Improved subjective and objective image quality assessment of JPEG image", International Conference on Information Communication and Embedded Systems (ICICES2014), 2014.
Crossref 9 words — < 1%
-
- 10 Jufriadif Na'am, Johan Harlan, Sarifuddin Madenda, Julius Santony, Catur Suharinto. "Detection of Proximal Caries at The Molar Teeth Using Edge Enhancement Algorithm", International Journal of Electrical and Computer Engineering (IJECE), 2018
Crossref 9 words — < 1%
-
- 11 www.nature.com
Internet 9 words — < 1%
-
- 12 link.springer.com
Internet 8 words — < 1%
-
- 13 Chhabra, Avneesh. "Incremental value of magnetic resonance neurography of Lumbosacral plexus over non-contributory lumbar spine magnetic resonance imaging in radiculopathy: A prospective study", World Journal of Radiology, 2016.
Crossref 8 words — < 1%
-
- 14 "Innovations in Computer Science and Engineering", Springer Science and Business Media LLC, 2017
Crossref 6 words — < 1%
-
- 15 Benjamin A. Stickler, Ewald Schachinger. "Basic Concepts in Computational Physics", Springer 6 words — < 1%

16 Bazila Hashia, Ajaz Hussain Mir. "Texture features' based classification of MR images of normal and herniated intervertebral discs", Multimedia Tools and Applications, 2018

6 words — < 1%

EXCLUDE QUOTES OFF
EXCLUDE ON
BIBLIOGRAPHY

EXCLUDE MATCHES < 5 WORDS